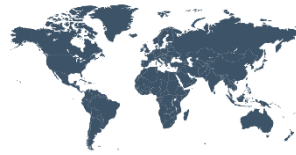

# Principles and Practice of Clinical Research

A Global Journal in Clinical Research



# PPCR

ISSN: 2378-1890

## Clinical Associations of Long Anterior Zonules: A Review

M. Khurana<sup>1\*</sup>

<sup>1\*</sup>Corresponding author: Mona Khurana, 18/41, College Road, Sankara Nethralaya Medical Research Foundation, Chennai 600006, India. Email: mona.insight@gmail.com

Received September 19, 2015; accepted October 15, 2015; published December 4, 2015.

### Abstract:

**Background and Aim:** The presence of long anterior zonules [LAZ] in the eye was first described in 1907. They have been reported to be associated with potentially blinding ocular diseases like retinal degeneration and glaucoma. Despite this it is understudied and little is known about their pathophysiology and natural history. This review discusses the different aspects of the long anterior zonule phenotype and suggests areas for further research.

**Methods:** We reviewed the available literature on eyes with LAZ and describe their characteristics and associations under different clinical subheadings.

**Conclusion:** Current evidence suggests that patients with long anterior zonules need to be investigated carefully for associated retinal disease and glaucoma. Asymptomatic cases need to be followed up closely for the development of these potentially blinding ocular diseases. Prospective studies are required to shed more light on the inheritance, pathogenesis and natural history of long anterior zonules.

**Key-words:** long anterior zonules, glaucoma, late onset retinal macular degeneration, pigment dispersion, pigmented lens striae

DOI: <http://dx.doi.org/10.21801/ppcrj.2015.13.3>

### INTRODUCTION

LAZ is the presence of abnormally long anterior zonules on the anterior capsule of the crystalline lens of the eye leading to a reduced zonule-free zone [Figure 1]. The normal anterior zonular insertion is about 1.5-2 mm anterior to the equator of the lens [Figure 2]. Any insertion beyond this is termed as an abnormally anterior zonular insertion [1, 2, 3] [Figure 3]. Entrapment of pigment in these anteriorly inserted long zonules gives them an appearance of brown, radial lines on the surface of the anterior lens capsule known as Pigmented Lens Striae [PLS] [4-6]. They have also been described as “opacifications striées coronaires superficielles du cristalline” [7] and “retro-iridial lines” [8]. Their exact mechanism is still unknown. Despite the potential association of this trait with glaucoma, retinal degeneration and its implications in cataract management not much is known about their pathogenesis. Few studies have looked at the long anterior zonule phenotype, its associations, and heredity. This review addresses different aspects of the long

anterior zonule phenotype which has been reported in literature.

### MORPHOLOGY

Fine radial pigmented lines on the anterior lens capsule were first described by Bruckner [5]. Vogt also described these lines in his atlas of slit lamp biomicroscopy [6].

Subsequently similar cases were reported over the next decades [2, 9-13].

Bruckner proposed that LAZ were remnants of vestige of the membrana capsulopupillaris [5]. Vogt postulated LAZ to be remnants of tunica vasculosa lenti due the presence of persistent pupillary membrane in some LAZ eyes [6]. This view was supported by Lugli, [9] Bellows [12] and other authors [9, 10, 11]. Roberts et al [14] found that subjects with long anterior zonules were 3.1 times more likely to have a persistent pupillary membrane in at least one eye. However association does not indicate causation. Long anterior zonules have been described to show changes with increasing age. Therefore, they may not be a remanents of membrane capsularis [4]. This view has also been supported by

histological studies [4, 21, 22]. Cowan et al suggested that they represent congenital deposition of pigment on zonular fibres [23]. Reiger examined 1,108 children and youths after mydriasis and found a prevalence of pupillary membrane in 64% [24]. Since none of these patients had any pigmented lens striae, they postulated that their formation was not due to regression of embryonic pupillary membrane but related to aging.

## DEMOGRAPHICS

Although long anterior zonules have been reported in a 17 year old girl [6] and a 24 year old boy [21] most of LAZ are found in an older age group mostly after the age of 40 years. The prevalence is noted to increase with each decade [25]. The prevalence in African Americans in a single clinic based study was 1.8% [25]. The reported prevalence from multiple ethnic groups in a single clinic study is about 2% [25, 30]. LAZ does not have a racial predilection and has been reported in African Americans, Americans, Europeans and Asians [20, 24, 26,]. It is more common in females [4, 20].

## OCULAR DIMENSIONS IN LAZ

Eyes with long anterior zonules have been observed to be more hypermetropic [ $+1.75\text{ D} \pm 1.82\text{ Diopter}$ ] and shorter [0.69 mm, 95% CI=0.34 to 1.04 mm,  $P<0.001$ ] than age, gender and race matched controls [2]. No difference in central corneal curvature has been noted. In African American females with LAZ no difference in ocular biometric parameters has been observed when compared to age and refractive error matched controls [27].

## GLAUCOMA AND LAZ

Presence of long anterior zonules is a potential risk factor for the development glaucoma. There are a few case reports in literature describing the association of long anterior zonules with both open angle glaucoma and angle closure disease. Not much is known about the most prevalent form of glaucoma or its pathophysiology in these eyes. Roberts et al reported [27-30] 7 cases (5 females, 2 males) of primary angle-closure disease in a case series of 61 African American patients with long anterior zonules. These eyes had shorter axial length and more hypermetropia as compared with controls. Both these characteristics are known risk factors for the development of primary angle closure disease.

Roberts et al also reported plateau iris as a cause of angle closure disease in 3 subjects with LAZ [29]. They proposed that a contraction of anomalous zonules could contribute to forward rotation of the ciliary body

processes leading to narrowing of the iridocorneal angle and subsequent angle closure glaucoma. Roberts et al reported 2 cases with open angle glaucoma, 1 with ocular hypertension and 2 with mixed mechanism glaucoma in their case series of African American subjects with LAZ [2]. In their cross sectional study of ocular dimension in LAZ eyes in African American females, Roberts et al observed 4 eyes with open angle glaucoma, 8 with ocular hypertension, 1 with normal tension glaucoma and 1 with mixed mechanism glaucoma [27]. 2 out of 7 patients with LAZ in Sturrock et als' case series had chronic glaucoma [4]. However, the details of gonioscopy were not clearly mentioned. Moroi et al reported 6 cases of glaucoma and 1 case of ocular hypertension in their series of 15 LAZ patients [20]. Their study population included subjects from multiple ethnicities including whites and Afghans.

LAZ has been associated with significant anterior segment pigment dispersion due to the apparent rubbing between the lens and iris pigment epithelium [28]. This causes iris pigment epithelial injury and subsequent pigment release [20]. Signs of pigment dispersion like Krukenberg spindle [30], diffuse posterior corneal pigmentation, dense trabecular meshwork pigmentation and iris atrophy have been reported in eyes with LAZ. With age-related lens thickening, the posterior lens surface remains constant and anterior lens surface moves forward increasing the zone of iris-lens contact and the amount of force exerted by structures upon one another. This may increase the amount of pigment dispersion with aging. The released pigment can lead to trabecular meshwork damage, decreased aqueous outflow facility and increased intra ocular pressure leading to glaucoma. This mechanism is distinct from pigment dispersion syndrome[PDS], in which the iridozonular contact occurs between the midperipheral iris and anterior zonule bundles. The clinical picture is also different from PDS which is seen more commonly in young myopic males with concave iris configuration, deep anterior chamber and a longer axial length [31]. Eyes with LAZ on the other hand are characterized by older age, female gender, hyperopia, shorter axial length along with the signs of intraocular pigment dispersion. Looking at the available evidence, it appears that pigment dispersion may contribute to the development of glaucoma in addition to the above mentioned mechanisms. Thus, the cause of glaucoma in eyes with long anterior zonules may be multifactorial.

## CATARACT SURGERY AND LAZ

Koch et al [32] reported 2 cases of LAZ with nuclear sclerotic cataract. Using a slit lamp beam [while

correcting for magnification] they found the zonule free zone to be in the range of 1.9-2.1mm. Interestingly, they also noted a decrease in the zonule free zone over a period of two years in one of these patients.

Kelty et al [33] reported the presence of LAZ encroaching centrally upto 2-2.5 mm in a patient with uveitis, raised IOP and mature cataract. They stained the capsule and zonules with indocyanine green intra operatively in order to highlight the LAZ. The anterior lens capsule can be stained with indocyanine green or trypan blue [19] during surgery for better intra-operative visualization of these zonules. The size of capsulorrhexis is debatable. Some authors suggest that the capsulorrhexis should be done within the zonule free zone [19] whereas some point out the potential complications associated with a small capsulorrhexis in eyes with zonule free zone less than 3 mm [33]. Kelty et al proposed that a 4-5 mm capsulorrhexis using a spiral technique is adequate in these eyes. The long anterior zonules have not been noted to show any fragility during standard phacoemulsification. No intra operative or post-operative complications like spontaneous lens subluxation, or zonular dehiscence have been reported [16]. There is no consensus regarding the use of a capsular tension ring [19, 33].

### LAZ AND RETINAL DEGENERATION

An ocular phenotype of LAZ and late-onset retinal macular degeneration [LORD/LORMD] in white families has been described in literature [20, 21, 34-37]. LORMD is an autosomal dominant retinal dystrophy characterized by progressive abnormalities in dark adaptation, retinal pigmentary atrophy, drusen like deposits and subsequent vision loss due to macular choroidal neovascular membrane. There is abnormal deposition of sub retinal lipofuscin with or without thickening of the Bruchs membrane. A clinical staging system has also been proposed where stage 1 comprises of younger asymptomatic patients with long anterior zonules and a normal fundus [38]. Some of these patients have iris atrophy, signs of pigment dispersion and glaucoma. With advancing age, these patients develop decreased dark adaptation, yellow spots in the macula, retinal pigmentary changes and vision loss due to macular choroidal neovascular membranes. Vitamin A supplementation was found to partially improve dark adaptation in some cases [21].

LORD is associated with a serine 163 arginine (S163R) mutation in the C1q tumor necrosis factor-related protein 5 gene. The CTRP5/C1QTNF5 gene is expressed in retinal pigment epithelium and ciliary epithelium [39], both of which are derived from neuro

ectoderm. It is related to collagen formation and basement membrane function. It is possible that the RPE expressing mutant secretes the abnormal material seen in LORD and the ciliary epithelium causes the pigment dispersion.

CTRP5 gene is closely associated with membrane frizzled related protein [MFRP] gene. MFRP appears primarily devoted to regulating axial length of the eye and mutations result in microphthalmia, nanophthalmos, angle closure glaucoma, and development abnormalities of the anterior segment [40]. Interactions of MFRP and CTRP5 require more research.

### CONCLUSION

To summarize, LAZ phenotype has at least two variants. One LAZ variety occurs in patients with genetic mutation and late onset retinal macular degeneration. The other type has unknown etiology and no known genetic mutation. This second type is associated with age >50 years, female gender, hyperopia and shorter axial length. Glaucoma and pigment dispersion have been reported in both variants. Eyes with LAZ can have primary angle closure disease, plateau iris, ocular hypertension, and normal tension glaucoma or mixed mechanisms glaucoma. Further studies are required to determine the most prevalent form of glaucoma in these eyes. After reviewing all the literature it is still unclear whether LAZ are present since birth and become clinically apparent later due to age related pigment dispersion or whether they develop later as a part of aging. Longitudinal studies in eyes with LAZ may shed more light on their pathophysiology. However, the presence of LAZ in the eye has important implications due their association with multiple sight threatening diseases and capsular management during cataract surgery. LAZ may serve as a surrogate marker of retinal degeneration and glaucoma or may be part of a disease complex. Prospective studies are required to gain insight into the natural history. Genetic studies could shed more light on the inheritance and pathogenesis. Current evidence suggests that patients with LAZ need to be investigated carefully for associated retinal disease and glaucoma. Asymptomatic patients require a close follow up for the development of potentially blinding ocular diseases.

### Conflict of interest and financial disclosure

The authors followed the International Committee or Journal of Medical Journals Editors (ICMJE) form for disclosure of potential conflicts of interest. All listed authors concur with the submission of the manuscript, the final version has been approved by all authors. The authors have no financial or personal conflicts of interest.

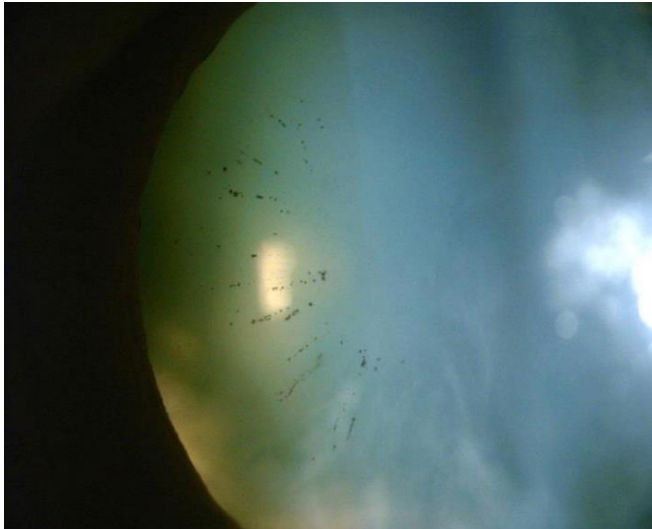


Fig. 1. Direct illumination slit lamp photograph showing the anterior insertion of pigmented long anterior zonules on the anterior lens capsule.

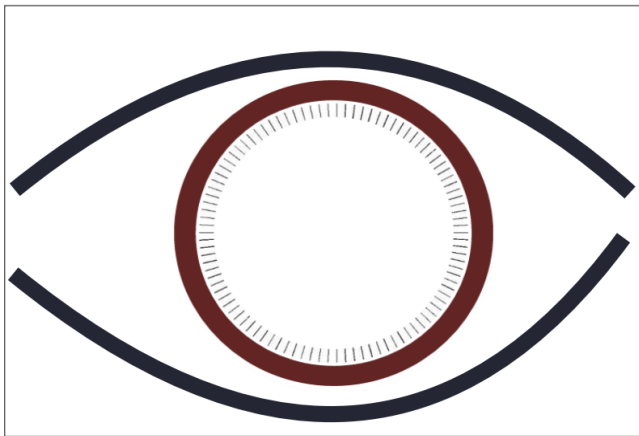


Fig. 2. Diagrammatic representation of the normal zonular insertion on the anterior lens capsule as seen in a dilated pupil

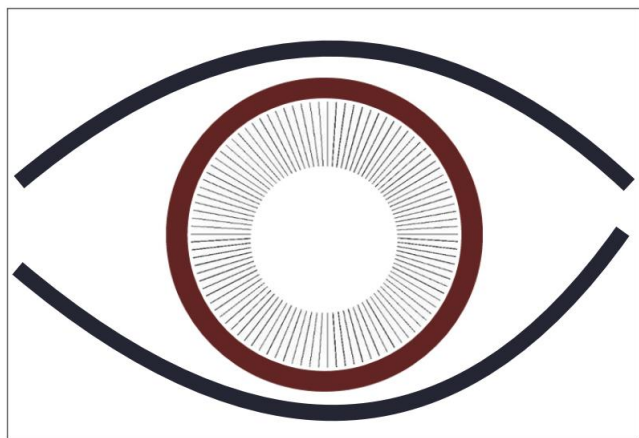


Fig. 3. Diagrammatic representation of abnormally anterior insertion of the long anterior zonules on the anterior surface of the crystalline lens capsule as seen in a dilated pupil

## REFERENCES

1. Sakabe I, Oshika T, Lim SJ, et al. Anterior shift of zonular insertion onto the anterior surface of human crystalline lens with age. *Ophthalmology* 1998;105:295–99.
2. Roberts DK, Ayyagari R, McCarthy B, et al. Investigating ocular dimensions in African Americans with long anterior zonules. *J Glaucoma*. 2013;22:393–97.
3. Lim SJ, Kang SJ, Kim HB, et al. Analysis of zonular-free zone and lens size in relation to axial length of eye with age. *J Cataract Refract Surg* 1998; 24: 390–96.
4. Sturrock GD, Tripathi RC. Pigmented lens striae. *Br J Ophthalmol* 1976;60:287–93.
5. Bruckner A. Über Persistenz von Restender Tunica vasculosa lentis. *Arch Augenheilkd* 1907;56: Erg.H.
6. Vogt A. *Lehrbuch und Atlas der Spaltlampenmikroskopie*. 2nd ed. Berlin: Springer: 1931:2:367-83.
7. Abramowicz I. Opacifications striées coronaires superficielles du cristallin. *Ann D'Oculistique* 1933;170:602–04.
8. Berliner ML. *Biomicroscopy of the eye, slit lamp microscopy of the living eye*. New York: Paul B. Hoeber, Inc.; 1960: 1023–1024.
8. Lugli L. *Rass.ital.Ottal* 1933;2:1334
9. Streiff EB. *Indagine biomicroscopica sui residui delle tunica vascolare retro iridea del cristallino*. *Atti del XXXIII congr.della Soc.Oftal.ital* 1935;89.
10. Bischler, V. *Klin.Mbl.Augenheilk* 1939;103:517.
11. Bellows JG. Pigmented lines in retroiridal region of anterior capsule of lens. *Arch Ophthalmol*. 1944;32:483–84.
12. Cowan TH. Pigmentation and coloration of the lens. *Surv Ophthalmol* 1961;6:630–47.
13. Roberts DK, Newman TL, Roberts MF, et al. Remnants of the anterior tunica vasculosa lentis and long anterior lens zonules. *J Glaucoma* 2014;23:441-45.
14. Roberts DK, Yang Y, Moretton CE, et al. Quantification of long anterior lens zonules and their resulting zonule-free zone sizes. *Clin Experiment Ophthalmol* 2015;43:773-75.
15. Roberts DK, Yang Y, Wilensky JT. Cataract surgery in African Americans with long anterior lens zonules. *Clin Experiment Ophthalmol* 2014, 42: 898–900.
16. Hogan MJ, Alvarado JA, Weddell JE. *Histology of Human Eye: An Atlas and Textbook*. Philadelphia, PA: W.B. Saunders, 1971.
17. Farnsworth PN, Shyne SE. Anterior zonular shifts with age. *Exp Eye Res* 1979;28:291–97.
18. Chen SD, Glover N, Patel CK. Trypan blue staining of anteriorly placed zonules in patients with pigment dispersion. *J Cataract Refract Surg*. 2004;30:2462-63.
19. Moroi SE, Lark KK, Sieving PA, et al. Long anterior zonules and pigment dispersion. *Am J Ophthalmol* 2003; 136:1176.
20. Ayyagari R, Mandal MN, Karoukis AJ, et al. Late-onset macular degeneration and long anterior lens zonules result from a CTRP5 gene mutation. *Invest Ophthalmol Vis Sci* 2005;46:3363-71.
21. Larsen FE, Hvidberg J. Vogt's retro-iridian pigment lines. Light microscopical and ultrastructural study of a case. *Acta Ophthalmol (Copenh)* 1976; 54: 641–53.
22. Cowan TH. Pigmentation and coloration of the lens. *Surv Ophthalmol* 1961;6:630–47.
23. Reiger G. Radial retroiridian linear pigmentation. *Br J Ophthalmol* 1981;65:760-65.
24. Roberts DK, Lo PS, Winters JE, et al. Prevalence of pigmented lens striae in a black population: a potential indicator of age-related pigment dispersal in the anterior segment. *Optom Vis Sci*. 2002;79:681–87.
25. Jeong JH, Kim SG, Lee JH, et al. A Case of Long Anterior Lens Zonule and Pigment Dispersion Syndrome. *J Korean Ophthalmol Soc* 2014;55:133-37.
26. Roberts DK, Teitelbaum BA, Castells DD, et al. Anterior Chamber Depth, Lens Thickness, and Related Measures in African American Females With



- Long Anterior Zonules: A Matched Study With Control for Refractive Error. *J Glaucoma* 2014.
27. Roberts DK, Winters JE, Castells DD, et al. Pigmented striae of the anterior lens capsule and age-associated pigment dispersion of variable degree in a group of older African-Americans: an age, race, and gender matched study. *Int Ophthalmol* 2001;24:313–22.
  28. Roberts DK, Ayyagari R, Moroi SE. Possible association between long anterior lens zonules and plateau iris configuration. *J Glaucoma* 2008;175:393-96.
  29. Roberts DK, Winters JE, Castells DD, et al. A cross-sectional study of Krukenberg spindles and pigmented lens striae in a predominately black population: two highly associated clinical signs of anterior segment pigment dispersal. *J Glaucoma* 2005;14:57–63.
  30. Campbell DG, Schertzer RM. Pathophysiology of pigment dispersion syndrome and pigmentary glaucoma. *Curr Opin Ophthalmol* 1995;6:96-101.
  31. Koch DD, Liu JF. Zonular encroachment on the anterior capsular zonular-free zone. *Am J Ophthalmol* 1988;106:491–92.
  32. Kelty PJ, Snyder ME, Schneider S. Indocyanine green staining of anteriorly placed zonules. *J Cataract Refract Surg*.2003;29:2229–31.
  33. Subrayan V, Morris B, Armbrecht AM, et al. Long anterior lens zonules in late-onset retinal degeneration (LORD). *Am J Ophthalmol* 2005;140: 1127–29.
  34. Soumplis V, Sergouniotis PJ, Robson AG, et al. Phenotypic findings in C1QTNF5 retinopathy (late-onset retinal degeneration) *Acta Ophthalmol* 2013; 91: e191–e195.
  35. Jacobson SG, Cideciyan AV, Wright E, et al. Phenotypic marker for early disease detection in dominant late onset retinal degeneration. *Invest Ophthalmol Vis Sci* 2001;42: 1882–90.
  36. Aye KH, Gupta R, Talks SJ, Browning AC. Treatment of a choroidal neovascular membrane in a patient with late-onset retinal degeneration (L-ORD) with intravitreal ranibizumab. *Eye* 2010; 24: 1528– 1530.
  37. Borooah S, Collins C, Wright A, Dhillon B. Late-onset retinal macular degeneration: clinical insights into an inherited retinal degeneration. *Br J Ophthalmol* 2009;93:284-9.
  38. Mandal MN, Vasireddy V, Reddy GB, et al. CTRP5 is a membrane-associated and secretory protein in the RPE and ciliary body and the S163R mutation of CTRP5 impairs its secretion. *Invest Ophthalmol Vis Sci*. 2006;47:5505-13.
  39. Sundin OH, Leppert GS, Silva ED, et al. Extreme hyperopia is the result of null mutations in MFRP, which encodes a Frizzled-related protein. *Proc Natl Acad Sci U S A* 2005;102:9553-58.